



PATIENT

Tribi Perez

SPECIES

Canine

BREED

Shih Tzu

SEX

Male Neutered

AGE

8 years

WEIGHT

19.2lbs

INTERPRETED BY

Maggie Machen Lamy,
DVM, DACVIM
(Cardiology)

IMAGING PERFORMED BY

G. Ferrer, DVM

HOSPITAL NAME

Paseos Veterinary
Center

REFERRING VET

Dr. Nazario

PRESENTING CLINICAL SIGNS

History: History of grade 4/6 heart murmur and hypertension, no improvement has been seen with medication. BP: 169mmHg.

-Current medications: Amlodipine 2.5mg SID, Pimobendan, Furosemide, Enalapril, Besylate, Benazepril.

ECHOCARDIOGRAM FINDINGS

2D, m-mode, color flow and doppler imaging is available. Mild diffuse thickening of mitral valve leaflets with mild prolapse into the left atrial lumen. Mild eccentric mitral regurgitation with mild left atrial dilation. Normal MR velocity. Normal LV diameter with adequate myocardial function. The LV wall thickness is normal without evidence of chronic pressure overload. The tricuspid valve appears normal with trace tricuspid regurgitation. Normal velocity. Normal right atrial and ventricular diameter and morphology indicating no overt evidence of pulmonary arterial hypertension. The pulmonic and aortic valves are normal in morphology and mobility. Normal pulmonic and aortic outflow velocities with laminar flow. No obvious aortic or pulmonic insufficiency. No pericardial or pleural effusion noted. No obvious cardiac masses.

CARDIAC CHART

CANINE CARDIAC PARAMETERS	MR VMAX (m/s)	TR VMAX (m/s)	LA/AO (Boon method)	LA/AO (Heart Base; Swe)	FS (%)	EF (%)	EPSS (cm)
NORMAL PARAMETER	4.5-5.5	<2.7	1.3	<1.6	28-40	40-100	<0.6
PATIENT	5.4	2.7	NM	1.4	62	92	0.18
CANINE CARDIAC PARAMETERS	HR (BPM)	AV VMAX (m/s)	PV MAX (m/s)	BODY WEIGHT (kg)	LA 2D short axis Base view (cm)	LVIDd Avg; 2D and m-mode short axis (cm)	LVIDs Avg; 2D and m-mode short axis (cm)
NORMAL PARAMETER	50-100	0.7-1.7	0.7-1.6	BELOW	BELOW	BELOW	BELOW
PATIENT	86	1.2	1.4	8.7	1.7	2.6	1.0
*Normal chamber parameters expressed as a mean value (SD)				3	1.27 (5.3)	2.46 (2.46)	1.36 (5.5)
BODY WEIGHT DEPENDENT PARAMETERS				5	1.40 (4.5)	2.74 (5.2)	1.60 (4.7)
<i>*Note: All measurements based upon multi-modal images and methods. An average value is reported.</i>				10	1.50 (3.8)	3.27 (3.5)	2.06 (3.1)
				15	1.83 (2.0)	3.71 (2.4)	2.43 (2.1)
				20	2.02 (1.9)	4.14 (2.2)	2.80 (2.0)
				25	2.18 (2.4)	4.48 (2.9)	3.10 (2.5)
				30	2.33 (3.3)	4.83 (3.9)	3.39 (3.4)
				35	2.48 (4.3)	5.17 (5.0)	3.69 (4.5)
				40	2.62 (5.2)	5.48 (6.1)	3.96 (5.4)
				50	2.88 (7.1)	6.07 (8.3)	4.46 (7.4)

INTERPRETATION OF THE FINDINGS & FURTHER RECOMMENDATIONS

Chronic degenerative valve disease causing mild mitral and trace tricuspid regurgitation. Lack of significant left atrial enlargement indicates the current risk for complication is low. No concurrent issues such as systolic dysfunction or pulmonary hypertension are noted in this study.

INVOICE

28529

DATE

1/24/23

Systemic hypertension is noted in the history without response to medication. That being said, the blood pressure on exam was minimally elevated at 169mmHg and can be a normal physiologic response. It is also important to note that systemic hypertension in dogs does not



PATIENT

Tribi Perez

develop secondary to cardiac issues; rather, secondary cardiac issues develop with chronic systemic hypertension (such as LVH, aortic insufficiency, etc). **No secondary issues are seen here.** If 170mmHg is as high as the pressures have been, this may simply be a stressed value as all blood pressure readings in dogs must be evaluated in light of patient's stress level. If the blood pressure is truly thought to be pathologically elevated, full systemic evaluation is recommended to screen for causes, such as renal disease or an adrenal tumor. Highly recommend consultation with an IM specialist for true refractory SHT cases.

SPECIES

Canine

BREED

Shih Tzu

Based upon what is seen here, no cardiac medications are indicated, and **Pimobendan/Lasix can be safely discontinued.** Use of Amlodipine/ACEI should be dictated by blood pressure readings, both current and prior, finding of proteinuria, etc.

SEX

Male Neutered

Assessment of progression in the future will help predict long term prognosis, which is highly variable at this stage (B1). Omega fatty acid supplementation and mild salt restriction may be of some long-term benefit. Monitor for development of a cough, labored breathing, exercise intolerance or collapse episodes.

AGE

8 years

Anesthetic risk is considered mild if needed. Cardiac protective drug choices (opioid/benzodiazepine premedication, propofol or alfaxalone induction, isoflurane gas) are recommended. Pre-oxygenate for 5-10 minutes prior to induction. Monitor for arrhythmias, hypotension, and hypoxia both intra and post-operatively and intervene as necessary. Mild IV fluid restriction is recommended to avoid fluid overload. Avoid heart rate stimulating drugs such as atropine unless clinically indicated.

WEIGHT

19.2lbs

INTERPRETED BY

Maggie Machen Lamy,
DVM, DACVIM
(Cardiology)

PLAN

Reassess historical systemic hypertension as discussed and screen for underlying causes. IM consultation if indicated. No indication for Pimobendan or Lasix therapy.

Recommend conservative monitoring with a recheck echocardiogram in 6 months, sooner if any development of clinical signs.

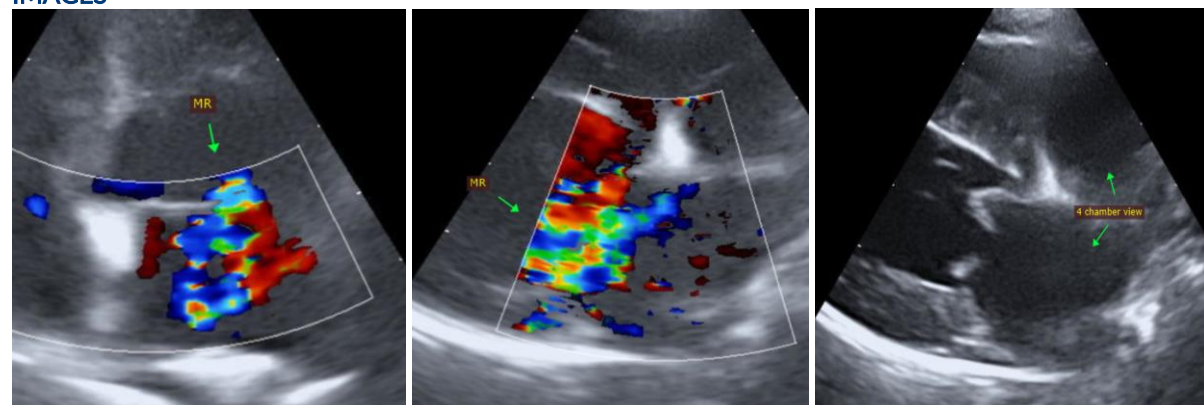
IMAGING PERFORMED BY

G. Ferrer, DVM

IMAGES

HOSPITAL NAME

Paseos Veterinary
Center



REFERRING VET

Dr. Nazario

INVOICE

28529

DATE

1/24/23

The information and recommendations provided are based on the images presented by the referring veterinarian. No evaluation can be communicated regarding pathology that was not visible in the image/video clips provided.

Thank you for this referral. This report was generated using transcription software, and minor dictation



PATIENT

Tribi Perez

errors may be present. If the clinical or image interpretation does not parallel your findings or if I can be of any further assistance, please contact me.

SPECIES

Canine

Maggie Machen Lamy, DVM

Diplomate of the American College of Veterinary Internal Medicine (Cardiology)

info@sonopath.com

BREED

Shih Tzu

SEX

Male Neutered

AGE

8 years

WEIGHT

19.2lbs

INTERPRETED BY

Maggie Machen Lamy,
DVM, DACVIM
(Cardiology)

**IMAGING
PERFORMED BY**

G. Ferrer, DVM

HOSPITAL NAME

Paseos Veterinary
Center

REFERRING VET

Dr. Nazario

INVOICE

28529

DATE

1/24/23